Doppler ultrasonography – the necessary skill for future nephrologists

Univerza v Ljubljani
Medicinska fakulteta

univerzitetni klinični center ljubljana
University Medical Centre Ljubljana

Jadranka Buturović Ponikvar

University Medical Centre Ljubljana
Medical Faculty, University of Ljubljana

Congress of nephrologists of Bosnia and Herzegovina, Tuzla, 17-20 October

Introduction

- In the last years, with advances in technology and availability of ultrasonography monitors, we are witnesses of the explosion of ultrasonopgrahy use in all fields of medicine, including emergency, intensive care, nephrology, dialysis and transplantation
- Ultrasonograpy is indespensable in guiding invasive procedures
- Ultrasonography is ideal for research (no harm, low cost, well accepted among patients, standardization necessary)
- **Overlooked benefit over other imaging procedures (CT, MR)**: during examination **close contact with the patient,** information added from this contact may improve quality of the examination and final conclusion

Outline

- Ultrasonography in renovascular disease
- Doppler ultrasonograpy in kidney transplantation
- Ultrasonography and interventional nephrology
  - Renal biopsies
  - Ultrasonography-guides insertion of hemodialysis catheters
  - Ultrasonography and arteriovenous fistulas/grafts

Renovascular disease – stenosis and occlusion

- Atherosclerosis (>90%) – ostial and proximal third of the mail tree of renal artery
- Fibromuscular dysplasia – mid- or distal third of the main renal artery tree, intrarenal arteries, 3-6% of normotensive kidney donors
- 6.8% older than 65 years*, progressive disease
- 18-20% patients with coronarography, 35-50% patients with aortography for peripheral arterial occlussive disease **
- **More and more patients coming in advanced phase of the disease (better survival of patients with aortic disease, less enthusiasm for diagnostic and intervention of renovascular disease after ASTRAL 2009 in CORAL 2014)**

*Hansen KJ, J Vasc Surg 2002; 36 (3): 443-51
** Garović VD, Textor SC. Circulation 2005; 112: 1362-74

Patophysiology of renovascular disease – new insights

- Studies with BOLD (blood oxygen level-dependent) MR: remarkable ability of kidney to adapt to moderate (30-40%) blood flow reduction with preservation of oxygen gradients
- Severe disease: histologic inflammation with extensive T cell and macrophage infiltration in addition to fibrosis
- Microvascular rarefication with partial collapse and obliteration of the arterial microcirculation
- Both hemodynamic and inflammatory component (unlike stenosis caused by FMD or renal transplant artery stenosis, with dominant hemodynamic component)
- **Once inflammatory component is active, resolving hemodynamics does not reverse or ameliorate progression of the disease**

Gained in Translation

Protective Paradigms for the Poststenotic Kidney

Hypertension. 2015;65:976-982.

Lilach O. Lerman, Stephen C. Textor

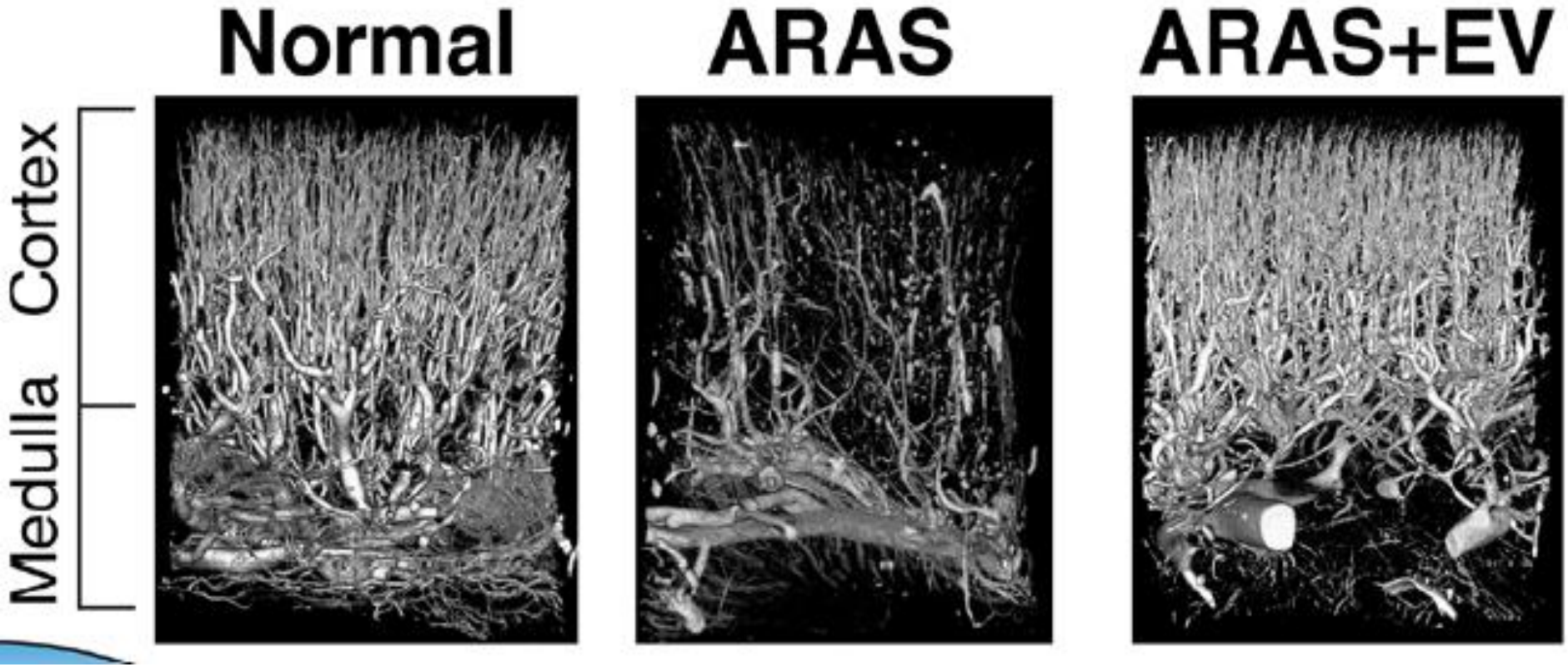

Micro-computed tomographic images showing microvascular loss in the posstenotic kidney which was rescued using mesenchymal cell derived extracellular vesicles (EV)

64-old CEO of the private company, referred for left renal artery stenosis and atrophic right kidney, "jet" 2.5 m/s, eGFR 45 ml/min, prot. 0, Th: ibersartan, aspirin, pravastatin. Two years later: eGFR 48 ml/min, proteinuria 0, "jet" 1.7- 1.8 m/s

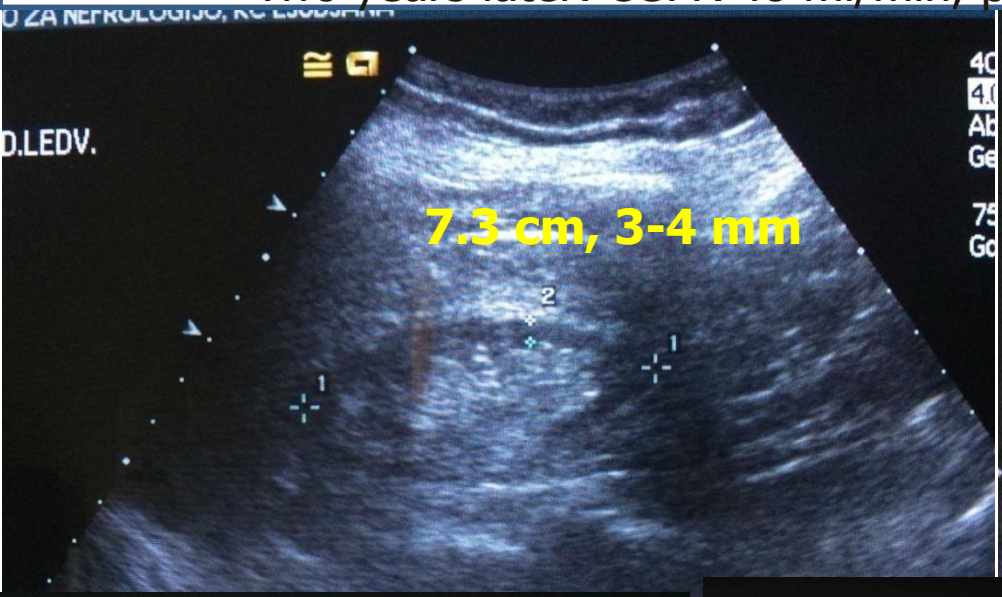

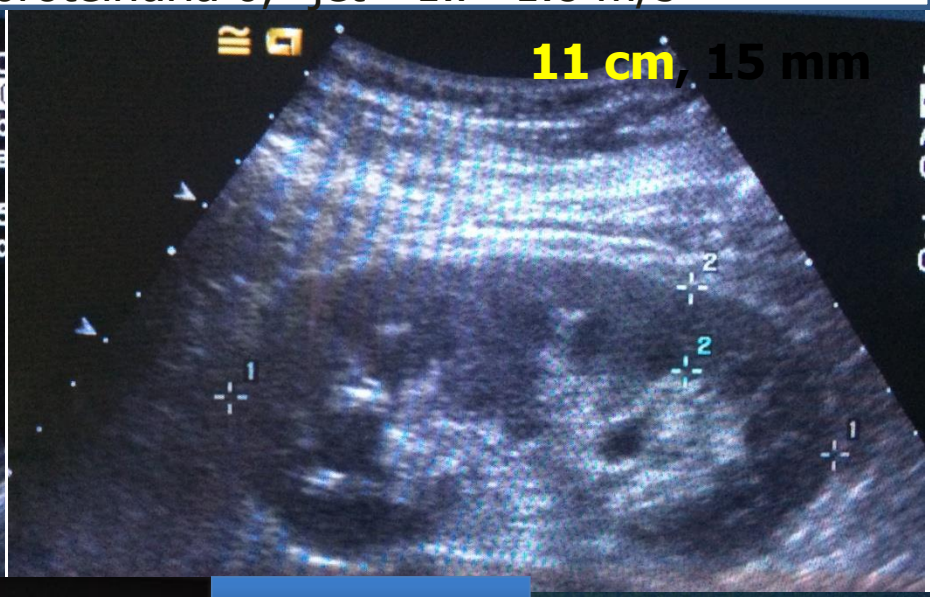

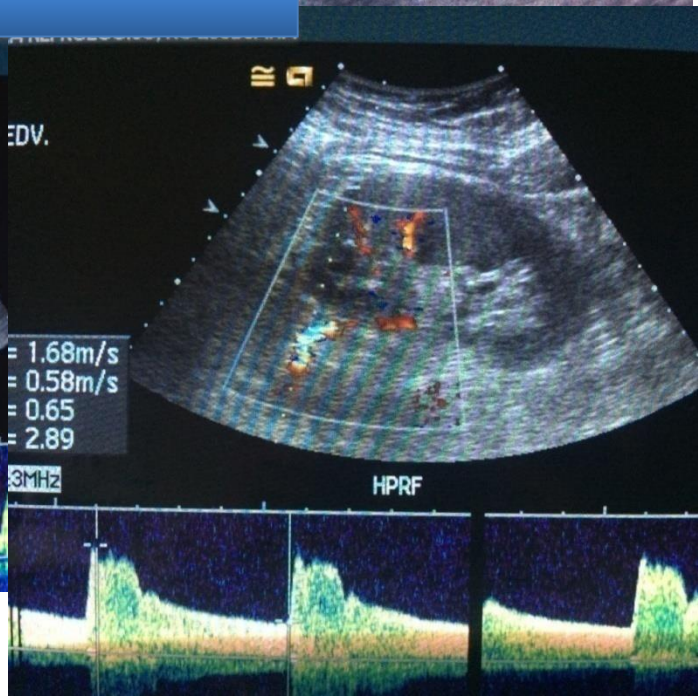

Clinical case 2

- 74-year old male, diffuse atherosclerosis, peripheral arterial disease, malignant hypertension, abdominal aorta aneurysm, stent graft at bifurcation
- Atrophic right kidney, normal left kidney (11.4 cm) with subocclusive renal artery stenosis (tardus-parvus)
- CKD stage 4: sCr 249 mmol/l, proteinuria 155 mg/day, eGFR 26 ml/min, stable for 1 year 10 months
- December 2016: pulmonary edema, anuria, hemodialysis for 2 weeks

UZ-Doppler leve ledvice:

Leva ledvica je normalno položena, gladkih kontur, vzdolžno meri do 11,4 cm, parenhim je dobro ohranjen, enakomerne debeline, premera 14-15 mm, rahlo bolj ehogen, z rahlo bolj poudarjenimi tekočinskimi piramidami - akutna komponenta dogajanja? Ni dilatacije votlega sistema, ne najdem prepričljivih znakov za kamne.

Ledvica je dobro prekrvljena, tako globalno kot kortikalno, razdalja od najbolj distalno dopplersko zaznavne parenhimske žile do kapsule je 2,8-4 mm, morebitnih kapsulnih kolateral dopplersko ne zaznam. Intrarenalni arterijski signal, ki ga je nekoliko težje dobiti, je tardus-parvus: RI na nivoju segmentnih arterij 0,76, akceleracijski čas 180 ms, akceleracijski indeks 0,76 m/s2, hitrosti toka krvi na koncu diastole 4,7 cm/s, maksimalne sistolične hitrosti 19,5 cm/s, srčna fr. ob meritvah 68/min.

Meritve na nivoju hilusa: RI 0,71, AT 153, AI 0,81, EDV 5,3, PSV 18,3, sr. fr. ob meritvah 60/min.

Mnenje: Leva ledvica je »vredna« posega: lepa, velika do 11,4 cm, dobro ohranjen parenhim, dobro perfundirana, ohranjen arterijski tok krvi v celotni diastoli (kar govori proti zelo hudi okvari na nivoju mikrocirkulacije). Angioplastika je indicirana tudi s strani kliničnih problemov: težko vodljiva arterijska hipertenzija, pljučni edem ob bilateralni renovaskularni bolezni s sfrknjeno desno ledvico ter potreba po hemodializnem zdravljenju.

Glavni izziv je tehnična izvedljivost posega ob AAA.

Priloga: več slik
Prof. dr. Jadranka Buturović-Ponikvar, dr. med., višja svetnica
PS. Ultrazvočno preiskavo smo opravili na ultrazvočnem aparatu Acuson Siemens Sequoia

DIAGNOZE

PTRA – left renal artery (December 2016)

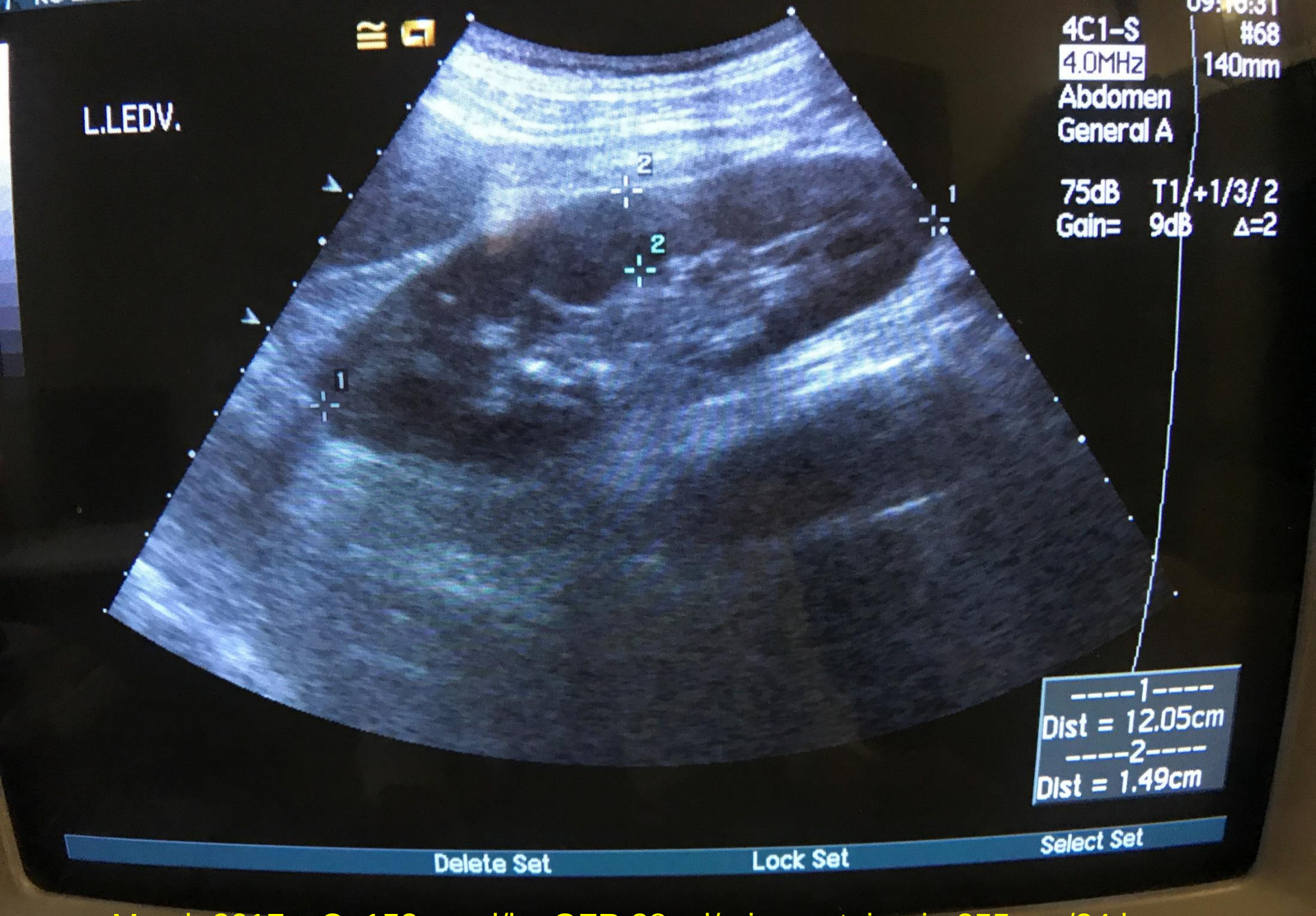

March 2017: sCr 152 umol/l, eGFR 38 ml/min, proteinuria 255 mg/24 h
October 2019: sCr 157 umol/l, eGFR 37 ml/min, proteinuria 200 mg/24 h

Outline

- Ultrasonography in renovascular disease
- **Doppler ultrasonograpy in kidney transplantation**
- Ultrasonography and interventional nephrology
  - Renal biopsies
  - Ultrasonography-guides insertion of hemodialysis catheters
  - Ultrasonography and arteriovenous fistulas/grafts

US-Doppler of kidney graft

- Easier to perform than US-Doppler of native kidneys
- Only one kidney to examine
- Superficially positioned, easy to locate
- Not moving with respiration
- Ideal model for teaching renal US-Doppler for young nephrologists
- However, anatomy of blood vessel anastomoses is unpredictable, surgery report may be helpful
- Main disadvantage: operator dependency (decreased with standardization of the examination and the report)

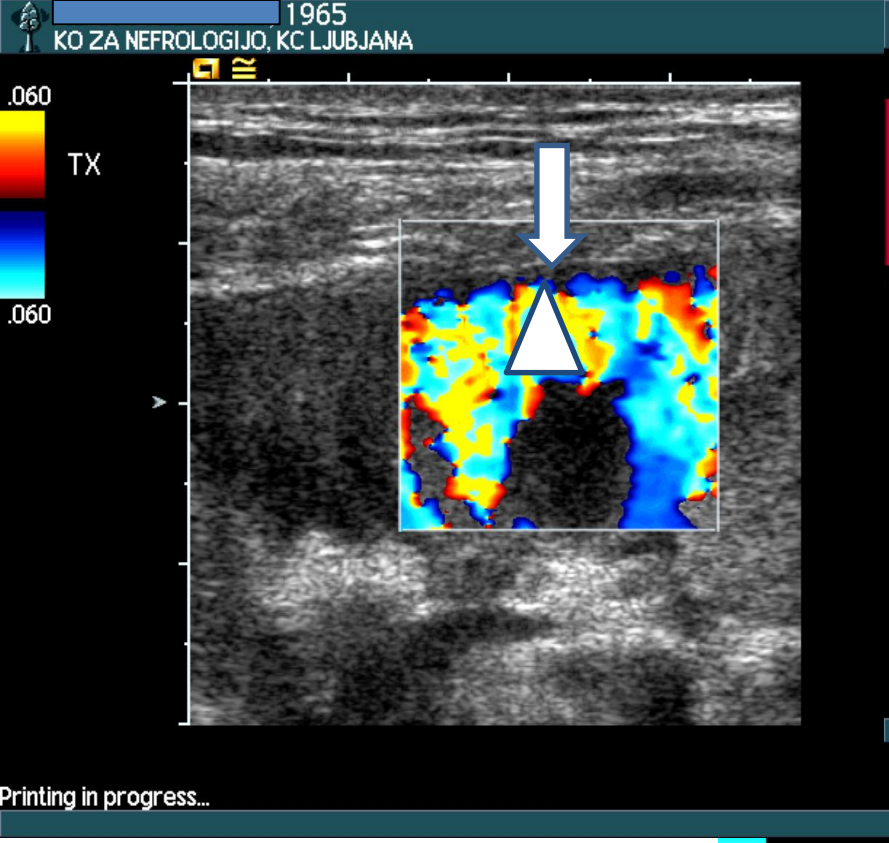

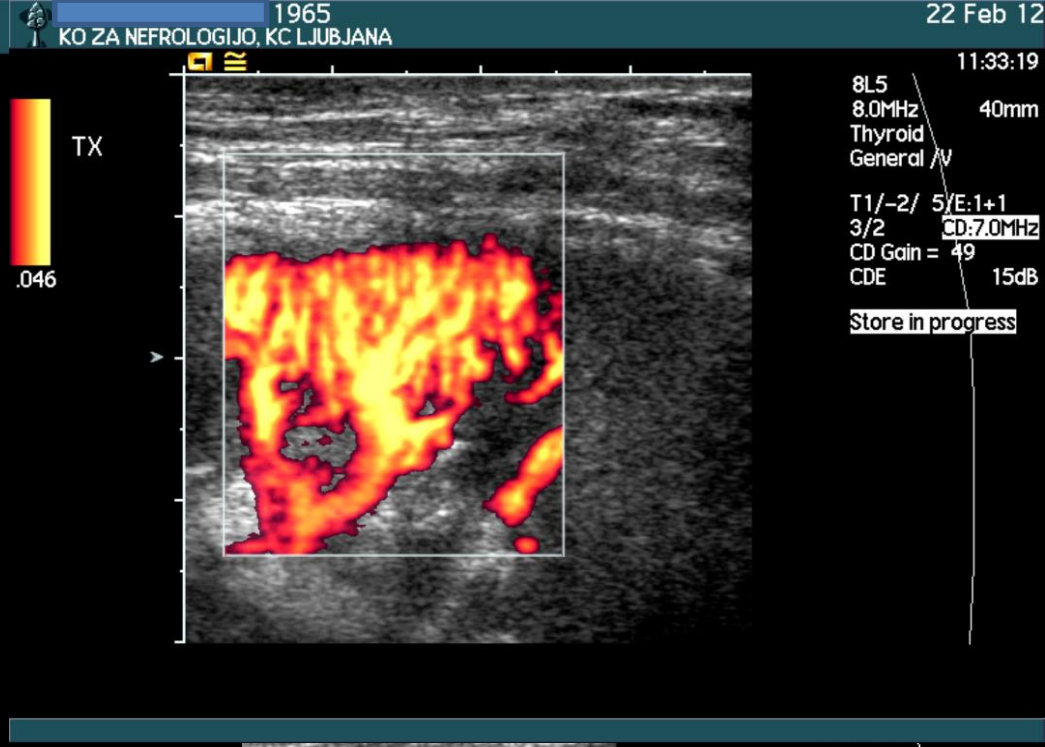

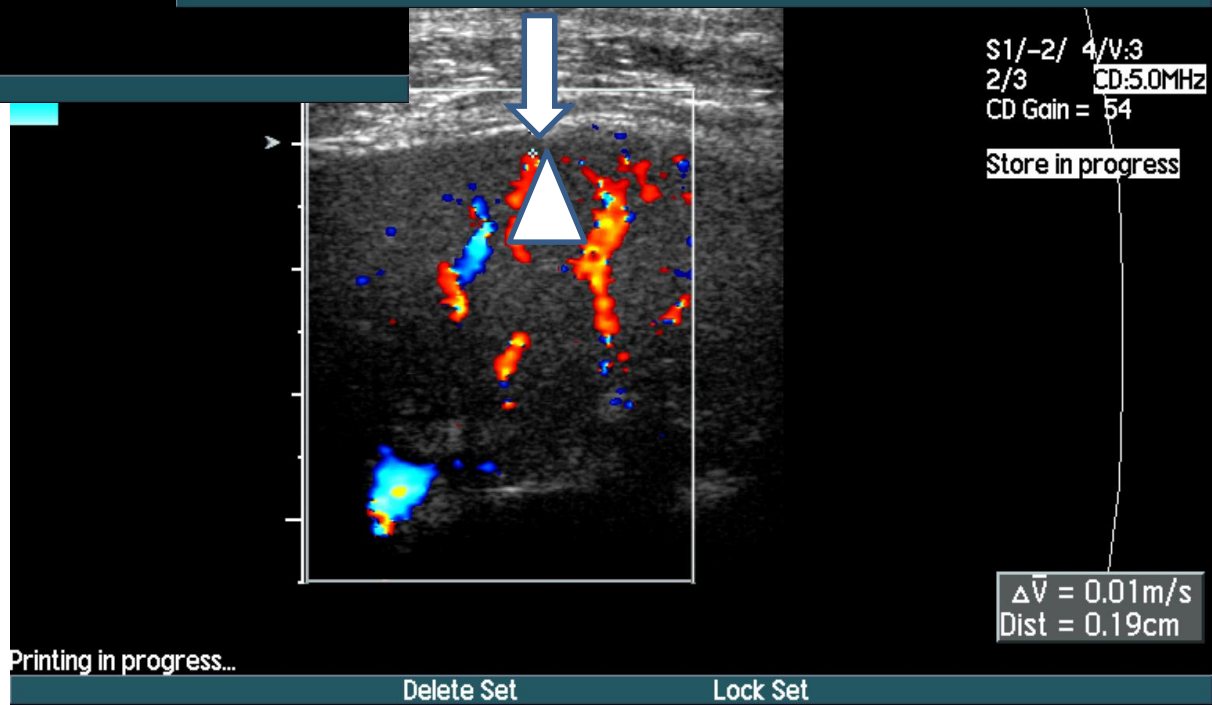

Microcirculation rarefication
Delayed graft function

SIEMENS

[redacted] 1995
19.10.17-10:12:07-DST-1.3.12.2.1107....

10:18:59 17.10.2019
KO ZA NEFROLOGIJO, UKC LJUBLJA...

PS=40.3 cm/s
ED=12.3 cm/s
RI=0.69
S/D=3.28
Acceleration=786.1 cm/s2
V1=12.5 cm/s
V2=40.8 cm/s
T=0.036 sec
HR=84 bpm
T=0.717 sec
PS=13.1 cm/s
ED=
RI=
S/D=

13
13 cm/s

39mm

40
20
cm/s
-20
10cm

Col1828

SIEMENS
6C1 HD
*KIDNEY - TX
General
TIS: 1,1
TIB: 3,0
MI: 1,0
12fps
2D – 100%
THI
H5,00 MHz
0dB / DR60
SC 2
DTCE M
MapE / ST2
C – 100%
CDV
3,50MHz
8dB Gen
PRF 1099
MapA / F2
D – 100%
PW
65dB DR40
GS 2,5
PRF 3005
F 90

(Full)
Set
Cal 1 Cal 2

Total: 3

ULTRAZVOČNO-DOPPLERSKI PREGLED TRANSPLANTIRANE LEDVICE (vsakodnevne meritve)

Ime: [redacted] Datum: [redacted] Ura: 11.03

Datum transplantacije: 5.2.2016

Pregled opravljen: a) KON b) Ko za urol c) UZ amb d) drugo

UZ monitor: a) Acuson b) Vivid 5 c) Vivid 6

Diureza predhodni dan (ml): 1050 Diureza prejšnjo uro (ml): ne meri urne

Kreatinin: 595

Zadnja HD po Tx: a) Ni bilo HD b) Datum HD: isto kot (29.2.) + 29.2. (PF+HD)

Functional AVF Yes No

Konveksna sonda: pregled v sterilnih pogojih da ne

Vzdolžni premer (cm) 10.8 Debelina parenhima (mm): 16.6 – hiperehogen

Globalna perfuzija: a) odlična b) dobra c) oslabljena d) drugo: _____

Doppler: Kortikalna perfuzija na konveksiteti (mm, 2-3 meritve): 4.4 – 5.3

Segmentna arterija, sredina centralne cone, 2-3 meritve: RI 0.75/0.79

Akceleracijski čas (ms): 13/20 Akceleracijski indeks (m/s2): 10.87/6.90

Končna diastolična hitrost (EDV, cm/s): 4.5/4.5 PSV 18.3/21

Zgodnji sistolični vrh da ne nakazan

Če je EDV 0, FTI: _____ Reverzija toka krvi v diastoli da ne

Heart rate

Linearna sonda:

Pregled: a) ni mogoč (globina, preglednost) b) ni časa c) opravljen

Pregled v sterilnih pogojih: da ne

Razdalja od kože do kapsule: 10 mm

Kortikalna perfuzija (mm, 2-3 meritve): 0.8/2.91

Linearna sonda (nivo meritev interlobarna arterija, sredina parenhima), 2- 3 meritve:

RI: 0.81/0.78

Akceleracijski čas (ms): 27/27 Akceleracijski indeks (m/s2): 2.47/4.08

EDV (cm/s): 1.4/2.8 PSV: 7.6/12.9

Zgodnji sistolični vrh da ne nakazan

Če je EDV 0, FTI (2-3 meritve): _____

Frekvenca srca: >100

9 x 9 cm hematom

Preiskavo opravil:

Pripombe:

Benefits of standardization

- Reducing operator dependency
- Improving quality of the examination and report
- Reducing time for high quality examination and report
- Easier comparison during follow-up and between different operators
- Easier training of young nephrologists
- Valuable in research, high quality data for retrospective studies

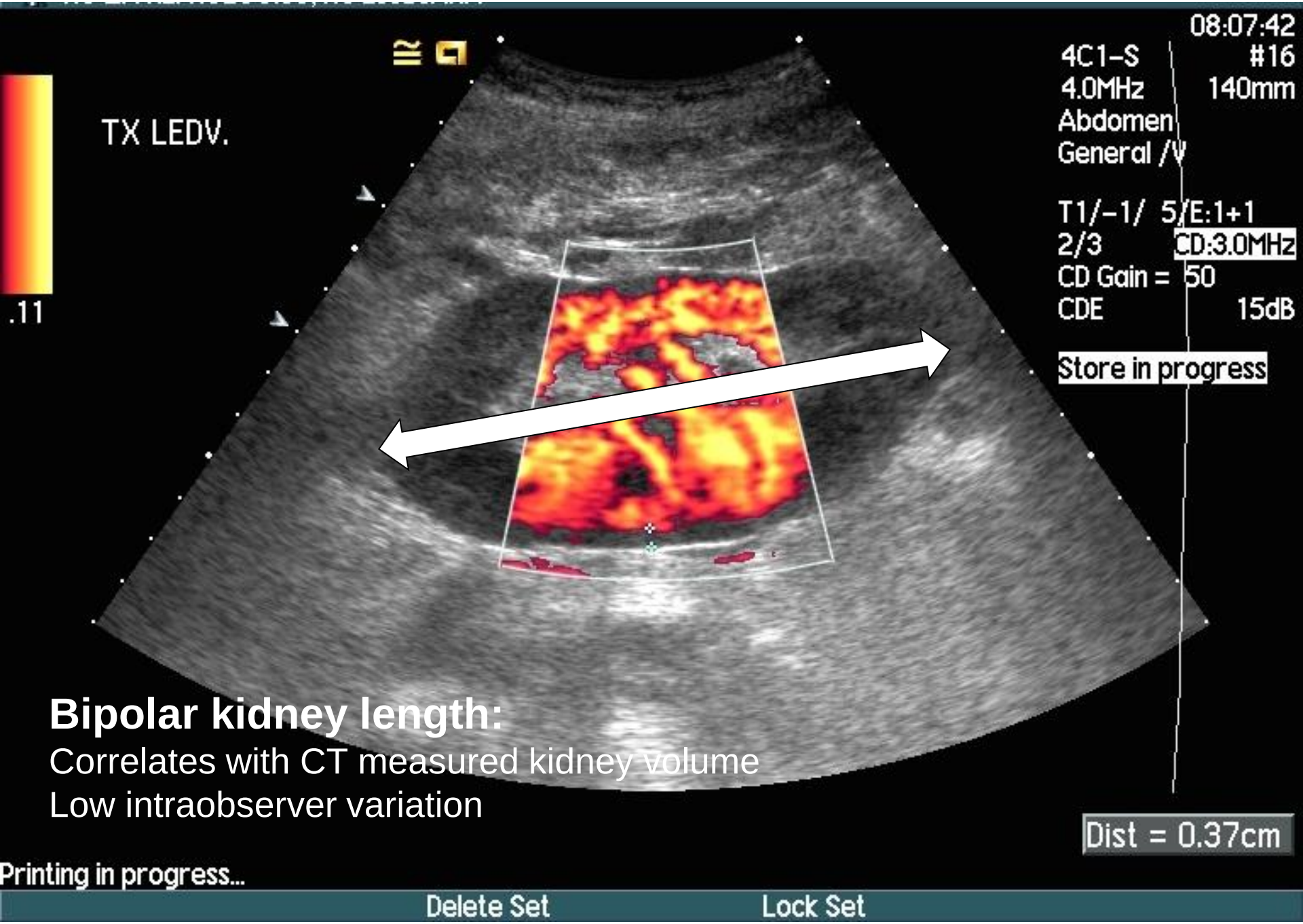

Bipolar kidney length:

Correlates with CT measured kidney volume

Low intraobserver variation

OPEN

Decrease in 1-year Kidney Graft Size Predicts Inferior Outcomes After Deceased Donor Kidney Transplantation

Senka Černe, MD,[1,2] Miha Arnol, MD, PhD,[1,3] Aljoša Kandus, MD, PhD,[1,3] and Jadranka Buturović-Ponikvar, MD, PhD[1,3]

Background. Longest bipolar length of the kidney graft is routinely measured for ultrasonographic assessment of graft size (GS), although the value of the graft length remains unclear. **Patients and Methods.** In a single-center, observational study involving 319 deceased-donor kidney transplant recipients, we assessed variations in absolute and adjusted GS (corrected for body surface area) between 1 and 12 months after transplantation ($\Delta GS_{1m \rightarrow 12m}$). We tested whether variations in GS during the first year were predictive of the composite outcome of a reduction of 50% or more in the estimated glomerular filtration rate or end-stage graft failure. **Results.** At 1 year after transplantation, 121 patients (38%) had a decrease in GS ($\Delta GS_{1m \rightarrow 12m} < 0$), and 198 patients (62%) had an increase in GS ($\Delta GS_{1m \rightarrow 12m} \geq 0$). After a median follow-up of 53 months, 41 patients with a decrease in GS reached the composite outcome as compared with 12 patients with an increase in GS (34% and 6%, respectively; $P < 0.001$). Areas under the receiver operating characteristics curves of absolute and adjusted $\Delta GS_{1m \rightarrow 12m}$ for composite outcome were 0.81 (95% confidence interval [95% CI], 0.74-0.88) and 0.78 (95% CI, 0.70-0.86), respectively. In multivariate analysis, the risk of the composite outcome was significantly higher among patients with a decrease in GS during the first year after transplantation (hazard ratio, 4.55; 95% CI, 2.35-8.81; $P < 0.001$). **Conclusions.** A decrease in kidney GS during the first year after transplantation, as compared with an increase in GS, is a powerful predictor of subsequent graft dysfunction or end-stage graft failure.

(*Transplantation* 2015;00: 00–00)

Transplantation 2016 Aug; 100 (8): 1759-66

Outline

- Ultrasonography in renovascular disease
- Doppler ultrasonograpy in kidney transplantation
- **Ultrasonography and interventional nephrology**
  - Renal biopsies
  - Ultrasonography-guides insertion of hemodialysis catheters
  - Ultrasonography and arteriovenous fistulas/grafts

Biopsy of native and transplanted kidney

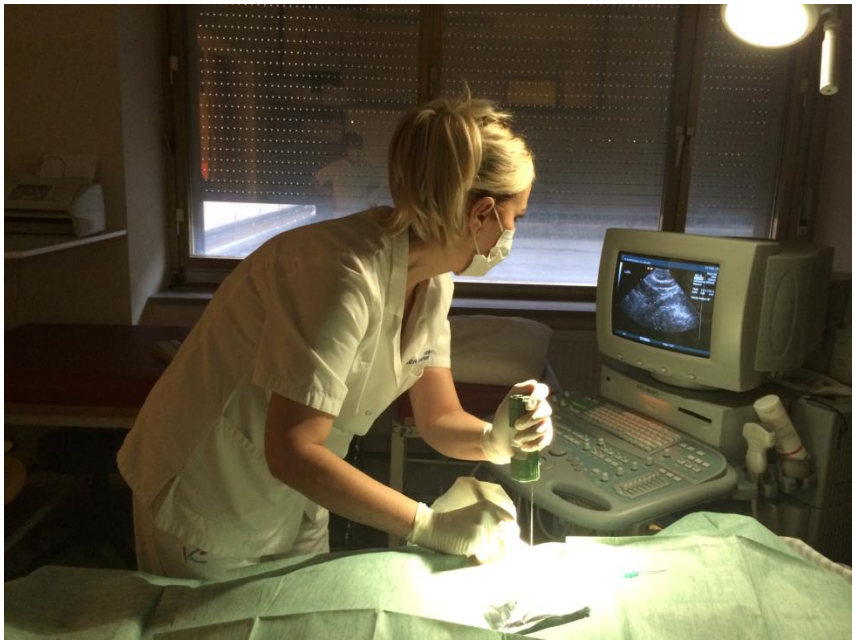

Active bleeding after second pass of the needle

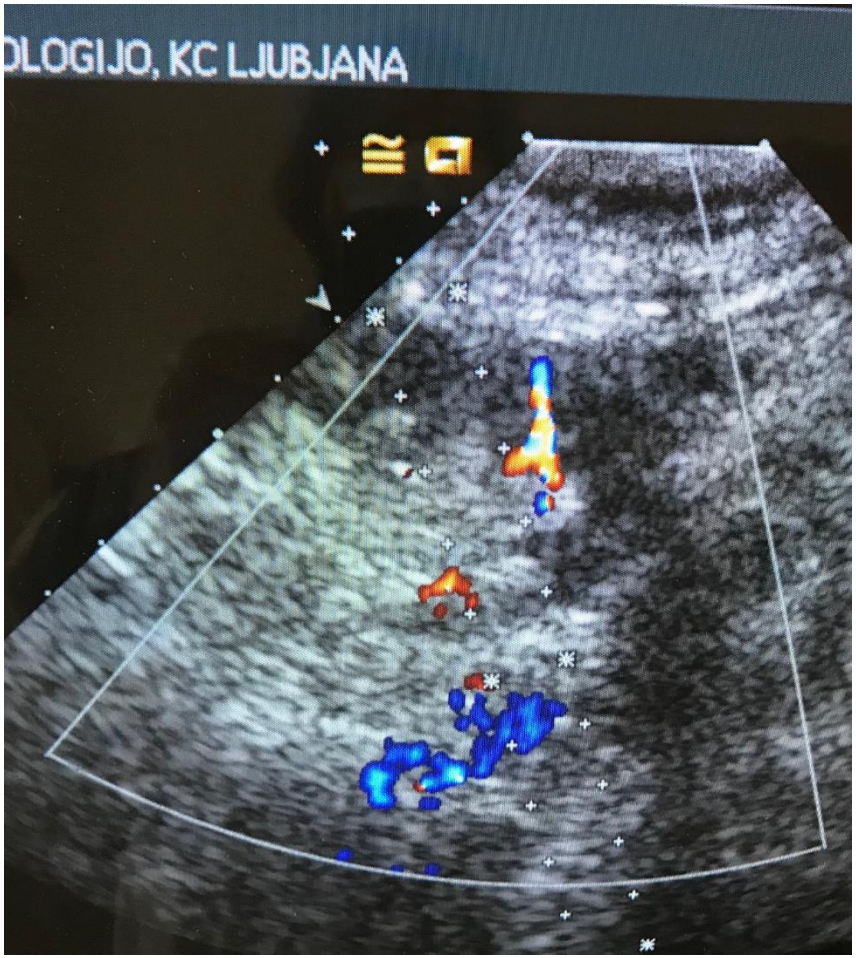

Bleeding stopped after 10 minutes compression

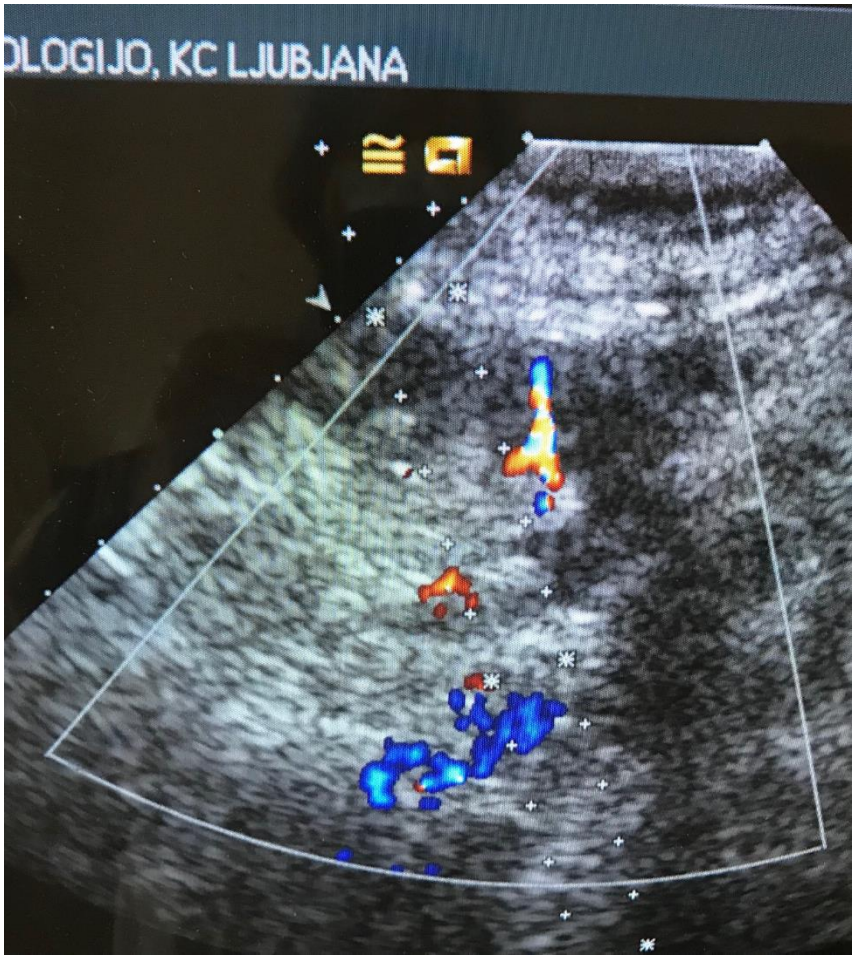

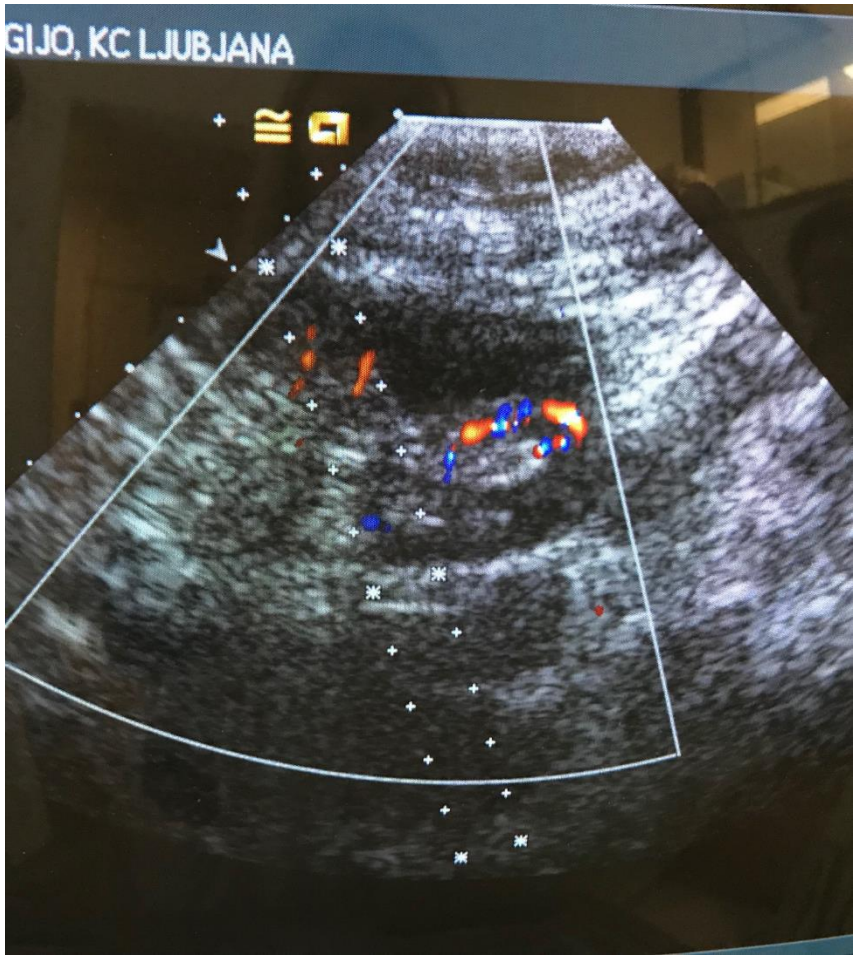

Clinical pathway for outpatient biopsy of kidney graft

6001

KLINIČNA POT ZA AMBULANTNO IZVEDBO LEDVIČNE BIOPSIJE (LB) PRI BOLNIKU S PRESAJENO LEDVICO

univerzitetni klinični center Ljubljana

Podatki o pacientu (priimek in ime, datum rojstva, matična številka) ali nalepka

PRIIMEK IN IME:

Datum rojstva:

MATIČNA ŠTEVILKA:

Center za transplantacijo ledvic
Klinični oddelek za nefrologijo

Priimek in ime bolnika:	Datum rojstva:
Datum biopsije:	Datum transplantacije:
Vrsta biopsije	☐ nadzorna ☐ indikacijska

CENTER ZA TRANSPLANTACIJO LEDVIC (izpolni zdravnik pred LB)	
Iz dokumentacije je razvidna indikacija za LB	☐ da
Bolnik se strinja z LB in ima podpisan pristanek	☐ da
Bolnik ima primeren UZ izvid za izvedbo LB	☐ da
Krvni tlak in pulz pred LB	☐ RR: ☐ pulz:
Zdravila, ki vplivajo na koagulacijo	☐ nima ☐ antiagreg. ☐ antikoagul.
Normalni testi hemostaze	☐ da ☐ ne; izvid:
Koncentracija Hb > 100 g/L	☐ da ☐ ne; izvid:
Priloženi podatki o virusnih markerjih in krvni skupini	☐ da ☐ markerji: ☐ krvna sk.:
Izpolnjena patohistološka napotnica	☐ da ☐ oznaka nujno

CENTER ZA TRANSPLANTACIJO LEDVIC (izpolni medicinska sestra / tehnik pred LB)	
Pripravljena in izpolnjena vsa dokumentacija	☐ da
Obveščena med. sestra / tehnik v ambulanti za UZ	☐ da
Obveščen Inštitut za patologijo MF	☐ da

AMBULANTA ZA UZ DIAGNOSTIKO (izpolni medicinska sestra / tehnik pred LB)	
Pripravljena in izpolnjena vsa dokumentacija	☐ da
Obveščen zdravnik, ki bo izvedel LB	☐ da
Obveščen tehnik iz Inštituta za patologijo MF	☐ da

e - verzija 2.0 klas. znak izpolnjenega obrazca: 6001 KP 0100 str.1/2

6001

KLINIČNA POT ZA AMBULANTNO IZVEDBO LEDVIČNE BIOPSIJE (LB) PRI BOLNIKU S PRESAJENO LEDVICO

univerzitetni klinični center Ljubljana

AMBULANTA ZA UZ DIAGNOSTIKO (izpolni zdravnik, ki dela LB)	
Izponjeni pogoji za ambulantno izvedbo LB	☐ da
Debelina biopsijske igle	☐ 18 G ☐ 16 G
Število vbodov	☐ 2 ☐ > 2, število:
Ura izvedbe LB	
Vzorci predani tehniku Inštituta za patologijo MF	☐ da
Tkivni vzorci makroskopsko ustrezni	☐ da ☐ posebnosti:
Kontrolni UZ-Doppler neposredno po LB	☐ ni znakov za zaplet ☐ hematom ☐ krvavitev ☐ AV fistula

AMBULANTA ZA UZ DIAGNOSTIKO (izpolni medicinska sestra / tehnik neposredno po LB)	
Krvni tlak in pulz po LB	☐ RR: ☐ pulz:
Položena obtežilna vrečka na punkcijsko mesto	☐ da
Bolnik prejme navodila glede postopka po LB	☐ da
Urejen prevoz bolnika v Center za transplantacijo	☐ da

CENTER ZA DIALIZO (izpolni medicinska sestra / tehnik po LB)	
Ura prihoda bolnika v Center za dializo	
Preverjena lega obtežilne vrečke	☐ da
Bolnik priključen na monitor za merjenje tlaka in pulza	☐ da
Prvi vzorec seča po LB	☐ bister ☐ krvav
Drugi vzorec seča po LB	☐ bister ☐ krvav
Zdravnik obveščen o krvnem tlaku, diurezi, barvi seča	☐ da

CENTER ZA TRANSPLANTACIJO LEDVIC (izpolni zdravnik pred odpustom)	
Krvni tlak in pulz pred odpustom	☐ RR: pulz:
Kontrolni UZ-Doppler pred odpustom	☐ ni znakov za zaplet ☐ hematom ☐ krvavitev ☐ AV fistula
Bolniku prejme navodila ob odpustu	☐ da
Ura odpusta bolnika iz Centra za transplantacijo	
Zdravnik, ki je izvedel LB	
Lečeči zdravnik ob odpustu	

e - verzija 2.0 klas. znak izpolnjenega obrazca: 6001 KP 0100 str.2/2

Safety and Complications of Percutaneous Kidney Biopsies in 715 Children and 8573 Adults in Norway 1988–2010

Clin J Am Soc Nephrol 7: 1591–1597, 2012.

Camilla Tøndel,† Bjørn Egil Vikse,*‡ Leif Bostad,§‖ and Einar Svarstad*‡*

- Radiologists 55.5%
- Nephrologists 33.5%
- Nephrologists and radiologists 13.1%
- Centres with < 30 biopsies per year – less complications
- Percentage of nephrologists performing kidney biopsies is decreasing
- The same trend is USA (radiologists performing kidney biopsies more than nephrologists)

“Hands-on” workshop for nephrology fellows, station renal biopsy, March 17, 2018

“Hands-on” workshop for nephrology fellows, station renal biopsy, March 17, 2018

“Hands-on” workshop for nephrology fellows, station renal biopsy, March 17, 2018

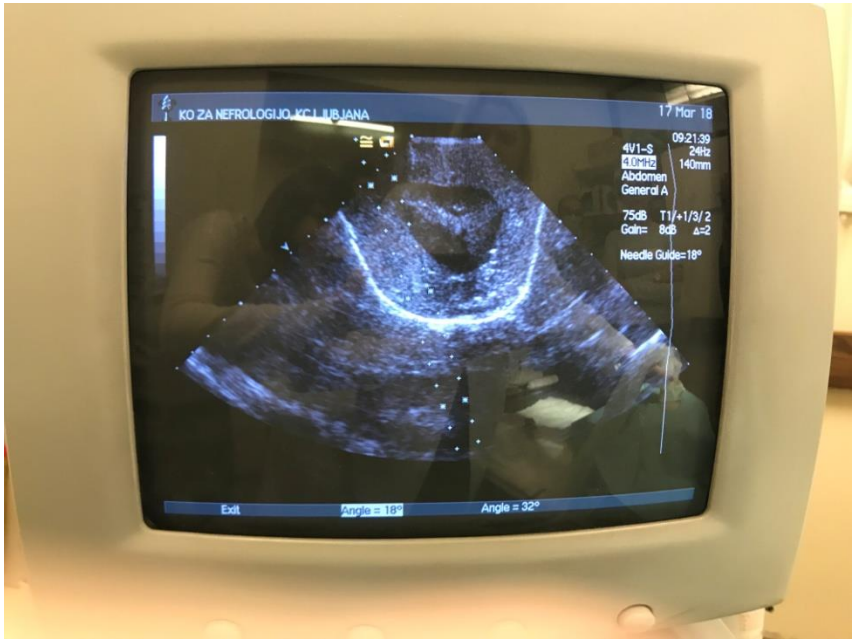

Ultrafest – organized by students, Medical faculty, University of Ljubljana, May 12, 2018

Ultrasonography and hemodialysis catheter insertion

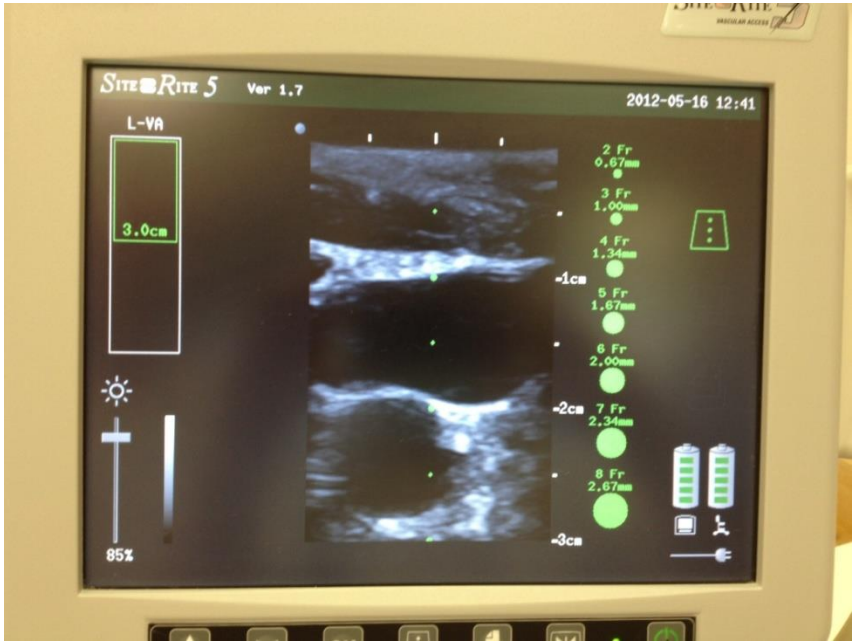

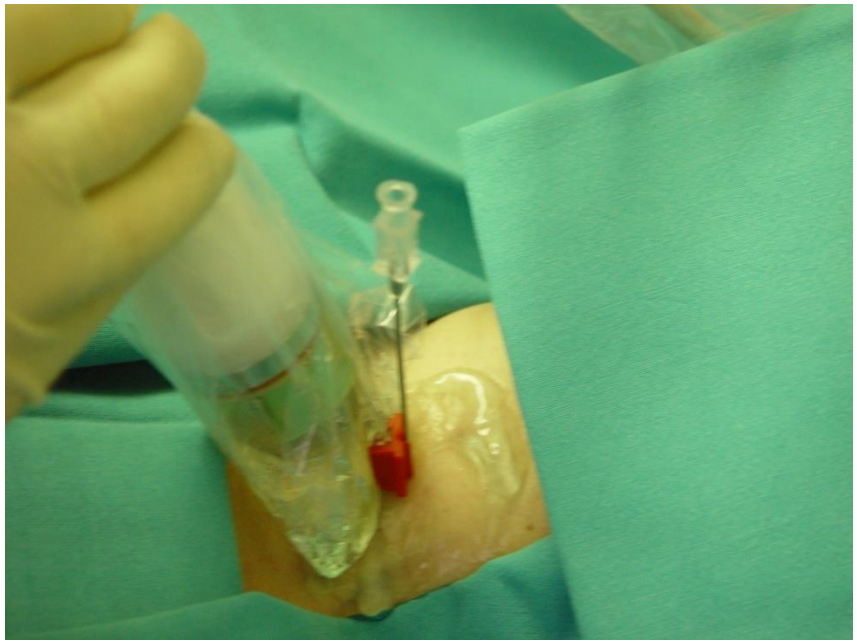

KLINIČNI CENTER LJUBLJANA
Interna klinika
Klinični oddelek za nefrologijo
Center za dializo
Ljubljana, Zaloška cesta 7

[redacted] 1990 8 2 [redacted]

UZ-Doppler pred konstrukcijo AV fistule:

Desno:
Ohranjena je lepa cefalična vena nadlakti, ki pod Esmarchom meri cca 4.5 mm, enakomerno široka in stisljiva od nivoja rame nazvdol do komolca.
Ohranjena je tudi cefalična vena podlakti, premera cca 3.0-3.5 mm od nivoja komolc navzdol do nivoja cca 8 cm nad zapestjem, pod tem nivojem se večkrat razveji in zoži.
Radialna art. v zapestju ima notranji premer 2.1 mm, stena je gladka, hitrosti so 20 cm/s.

Levo:
Ohranjena je cefalična vena nadlakti, enakomerno široka od nivoja rame navzdol do komolca, premera 4.5 mm pod Esmarchom.
Ohranjena je tudi cefalična vena podlakti, premera 3.0-3.2 mm, od nivoja komolca navzdol do zapestja, proti zapestju nekoliko zavije na lateralno stran.
Radialna art. v levem zapestju ima notranji premer 1.9 mm, stena je gladka, hitrosti so 18 cm/s.

Mnenje: Svetujem konstrukcijo AV fistule v levem zapestju. Potek vene je nekoliko lateralen. Možna je tudi konstrukcija AV fistule desno na podlakti, z anastomozo cc 8 cm nad zapestjem, ter kubitalnih fistul obojestransko.

Svetujemo program vaj stiskanja po protokolu, obročka dobi.

Vadba stiskanja pesti: vsak dan, stiskanje 20 stiskov na minuto, prvi teden vadbe šestkrat po 5 minut (dnevno), drugi teden vadbe 3-4 krat po 10 minut dnevno, od tretjega tedna dalje do vključno osmega tedna oz. do operacije naj stiska 2-3x dnevno po 15 minut.

Operacija bo v ponedeljek, 27. februarja 2006, ob 7.30, v Centru za dializo KC, lokalni anesteziji, operiral bo prof. Ponikvar.

Priloga: več slik

Prof. dr. Jadranka Buturović-Ponikvar, dr. med., višja svetnica

PS. Ultrazvočno preiskavo smo opravili na ultrazvočnem aparatu Acuson Sequoia/Siemens 512 (model 2004)

Preoperative ultrasonography mapping before arteriovenous fistula/graft construction

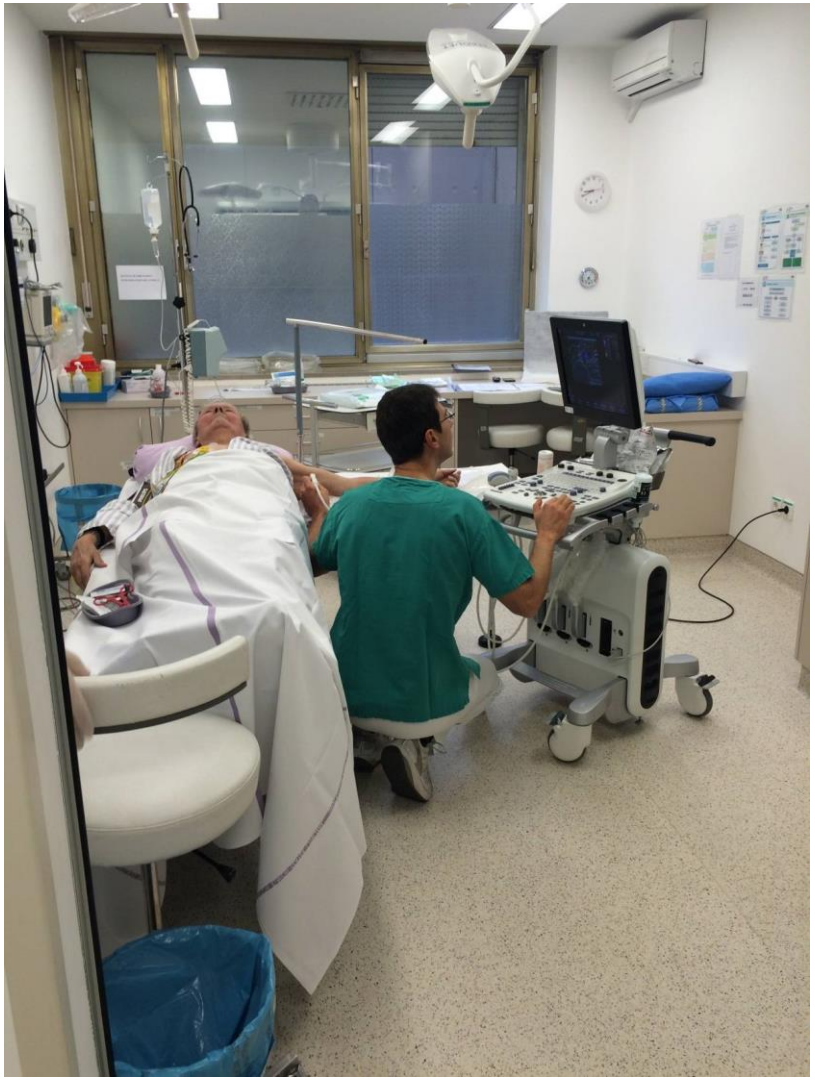

Retooling Nephrology with Ultrasound

W. Charles O'Neill[1] *and Daniel W. Ross*[2]

Clin J Am Soc Nephrol 14: ●●●–●●●, 2019. doi: https://doi.org/10.2215/CJN.10430818

We should not continue to practice nephrology and train future nephrologists the same way we did 25 years ago. Point-of-care ultrasound is rapidly becoming a standard component of patient care and failure to embrace it will leave us further behind, akin to physicians who never adopted the stethoscope. The difficulty in attracting trainees to our specialty is one symptom of this and a call to action. Point-of-care ultrasound is an exciting clinical tool and incorporating it into nephrology training is one way to improve the care of our patients and to attract future nephrologists. As demonstrated by other specialties and a growing number of nephrology training programs, this can be accomplished, but it will require a coordinated effort on the part of nephrology leadership, training programs, and certifying organizations.

Editorial

AJKD

Integrating Point-of-Care Ultrasonography Into Nephrology Fellowship Training: A Model Curriculum

AJKD Vol 74 | Iss 1 | July 2019

Abhilash Koratala, Mark S. Segal, and Amir Kazory

Comprehensive ultrasonography – areas where potentially no one can perform better than dedicated nephrologist

1)Renovascular disease
2)Arteriovenous fistula: preoperative mapping and Doppler of AV fistula with clinical problem
3) Doppler ultrasonography of kidney graft

Summary

- Ultrasonography is rapidly expanding in nephrology and other fields of medicine
- Today ultrasonography is indispensable in clinical nephrology, dialysis, transplantation and interventional nephrology
- Clinical knowledge of specific areas of nephrology is necessary for the optimal interpretation of ultrasonography exam
- Transplanted kidney is ideal for training in performing of renal Doppler

Training of ultrasonography in nephrology, dialysis and transplantation

- Nephrologists should be trained in ultrasonography like cardiologists and gynaecologists are for decades
- Training in specific Doppler ultrasonography areas should be divided into basic (point-of-care, “bedside”) and comprehensive
- I believe that all young nephrologists should perform basic ultrasonography
- As concerns comprehensive ultrasonography, I believe that no one can perform in better than dedicated nephrologists in the areas of: renovascular disease, vascular access and transplanted kidney

Retooling Nephrology with Ultrasound

W. Charles O'Neill[1] *and Daniel W. Ross*[2]

Clin J Am Soc Nephrol 14: ●●●–●●●, 2019. doi: https://doi.org/10.2215/CJN.10430818

1. Establishment of criteria for training and competence of faculty, primarily through adoption of existing guidelines.

We should not continue to practice nephrology and train future nephrologists the same way we did 25 years ago. Point-of-care ultrasound is rapidly becoming a standard component of patient care and failure to embrace it will leave us further behind, akin to physicians who never adopted the stethoscope. The difficulty in attracting trainees to our specialty is one symptom of this and a call to action. Point-of-care ultrasound is an exciting clinical tool and incorporating it into nephrology training is one way to improve the care of our patients and to attract future nephrologists. As demonstrated by other specialties and a growing number of nephrology training programs, this can be accomplished, but it will require a coordinated effort on the part of nephrology leadership, training programs, and certifying organizations.

l courses,
centers of
gy fellows
programs
ria such as
kill set re-

KIDNEY BIOPSY IN THE VERY ELDERLY: TECHNICAL CONSIDERATIONS AND PROCEDURAL OUTCOMES

Jadranka Buturović Ponikvar, Miha Arnol, Vladimir Premru, Marko Malovrh, Jernej Pajek

Department of Nephrology, University Medical Center Ljubljana, Ljubljana, Slovenia

INTRODUCTION

Percutaneous kidney biopsy, introduced in 1951, was a major technological advancement that led to establishment of nephrology as the subspecialty in 1960. In the last 20 years there is a shift in who is performing biopsy towards radiologists (Korbet SM, CJASN 2012). The aim of our study was to evaluate technical considerations and procedural outcomes in kidney biopsy performed by nephrologists, in an increasingly complex group of patients - the very elderly.

METHODS

Retrospective analysis was performed in the cohort of patients aged 75 years or more undergoing native kidney biopsy in the period 2011-2016. Biopsies were performed by a single operator (5 experienced nephrologists), under real-time ultrasound (US) guidance, with immediate and next-day post-biopsy US-Doppler monitoring for complications. Data on indication, pre-biopsy serum creatinine, punctured kidney length and resistance index (RI), needle gauge (G), number of needle passes, immediate and next-day complication rate, cumulative core length and number of glomeruli in the sample were evaluated.

RESULTS

	No / Median	Range
Patients /Biopsies	97/101	-
Men	41	-
Age (years)	78	75-89
Serum creatinine (µmol/l)	269	55-770
Left kidney	95	-
Kidney length (mm)	105	72-133
Resistance index	0.82	0.51-1.0
Cummulative core length (mm)	27	5-47

Table 1. Data on patients' and procedure characteristics

Main indications for biopsy were nephritic syndrome in 61 (60%) patients, acute kidney injury in 21 (21%) and nephrotic syndrome/large proteinuria in 13 (13%) of patients.

Approximately half of the procedures (51, 51%) were performed using 18G needle, 36 (36%) by 16G and 14 (14%) with both needles (18G and 16G). 18G needle only was used in patients with higher age: median 79 vs. 78 years (p=0.002). In 44% biopsies more than 2 passes (punctures) were made. The cumulative median core length was 27 mm

RESULTS

	No
Immediate active bleeding	30
Immediate hematoma	21
Immediate arteriovenous fistula	3
Hematuria	2
Next-day hematoma	18
Next-day arteriovenous fistula	6

Table 2. Complications after 101 native kidney biopsies in the very elderly patients

No association was found between complication rate and age, prebiopsy serum creatinine, kidney length, RI and needle size. Immediate active bleeding was associated with immediate and next-day hematoma, but not with hematuria and AVF. There was a trend to larger percentage of immediate AVFs with more than 2 passes performed: 0 vs 7.3% (p=0.08). The median number of glomeruli per total sample was 16 (range 4-44). Biopsies with more than 2 passes provided larger cumulative core length: median 30 vs. 26,5 mm (p=0.07) and more glomeruli: median 18 vs 16 (p=0.04).

CONCLUSIONS

procedures and was predictive of immediate and next-day hematoma. Age, pre-biopsy creatinine, punctured kidney length and resistance index were not predictive of post-biopsy complications. Thinner 18G needle use provided equal number of glomeruli per sample as a larger, 16G needle. Immediate post-biopsy Doppler examination focused on active bleeding and hematoma predicted next-day hematoma and may be used to guide intensity of post-biopsy patient monitoring.

Clinical case: bilateral renal artery stenosis

- 37 years old male
- Peripheral artery disease, both femoral arteries occluded, strong collaterals
- Clinical manifestations resembles atherosclerosis
- Billateral ostial renal artery stenosis (CTA), left artery higher grade
- Normal renal function, creatinine clearance 90 ml/min, Biuret 80 mg/day

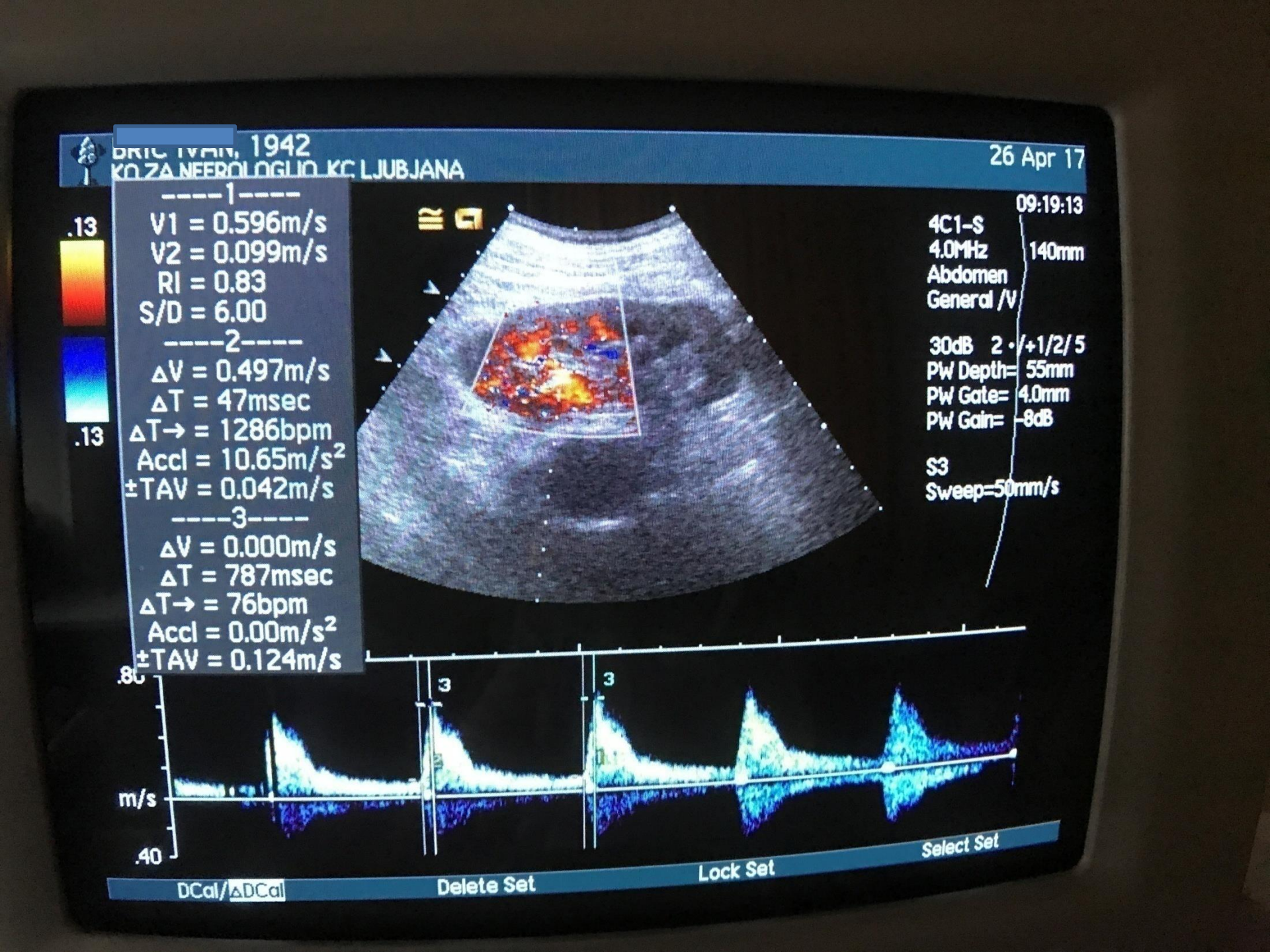
[redacted], 1942
KO ZA NEEROLOGIJO KC LJUBJANA
26 Apr 17
09:19:13
----1----
V1 = 0.596m/s
V2 = 0.099m/s
RI = 0.83
S/D = 6.00
----2----
ΔV = 0.497m/s
ΔT = 47msec
ΔT→ = 1286bpm
Accl = 10.65m/s²
±TAV = 0.042m/s
----3----
ΔV = 0.000m/s
ΔT = 787msec
ΔT→ = 76bpm
Accl = 0.00m/s²
±TAV = 0.124m/s
.13
.13
4C1-S
4.0MHz
Abdomen
General /V
140mm
30dB 2 •/+1/2/5
PW Depth= 55mm
PW Gate= 4.0mm
PW Gain= -8dB
S3
Sweep=50mm/s
.80
m/s
.40
3
3
DCal/ΔDCal
Delete Set
Lock Set
Select Set

[redacted]

[redacted]

KO ZA NEFROLOGIJO, KC LJUBJANA

D.LEDV.

4C1-S
4.0MHz
Abdomen
General

T1/-2/ 3/V:3
2/1 CD:3.0
CD Gain = 59

----1----
Dist = 0.17cm

1980

10 May 17

NEFROLOGIJO, KC LJUBJANA

----1----
= 0.325m/s
= 0.136m/s
= 0.58
= 2.39
----2----
= 0.136m/s
= 33msec
→ = 1800bpm
= 4.08m/s²
= 0.142m/s
----3----
= 0.030m/s
= 1060msec
→ = 57bpm
= 0.03m/s²
= 0.128m/s
----4----
Dist = 0.23cm
----5----
Dist = 0.21cm

09:18:15
0sec
140mm

4C1-S
4.0MHz
Abdomen
General

30dB 2 •/+1/2/5
PW Depth= 70mm
PW Gate= 4.0mm
PW Gain= 1dB

Sweep=50mm/s

[redacted]

D.LEDV.

4C1-S
4.0MHz
Abdomen
General A

75dB T1/+1
Gain= 1dB

A

Dist = 0.42cm

[redacted]

1980

KO ZA NEFROLOGIJO, KC LJUBJANA

D.LEDV.

4C1-S
4.0MHz
Abdomen
General /V

30dB 2 •/
PW Depth=
PW Gate=
PW Gain=

Sweep=50

V1 = 2.24m/s
V2 = 0.50m/s
RI = 0.78
S/D = 4.50

A

PW:3MHz

HPRF

2.0
m/s
1.0

[redacted]

L.LEDV.

[redacted]

10 May 17

ZA NEFROLOGIJO, KC LJUBJANA

09:31:10

----1----
V1 = 0.419m/s
V2 = 0.124m/s
RI = 0.70
S/D = 3.38
----2----
ΔV = 0.223m/s
ΔT = 33msec
ΔT→ = 1800bpm
Accl = 6.68m/s²
±TAV = 0.121m/s
----3----
ΔV = 0.005m/s
ΔT = 887msec
ΔT→ = 68bpm
Accl = 0.01m/s²
±TAV = 0.118m/s

4C1-S
4.0MHz 140mm
Abdomen
General /V

30dB 2 •/+1/2/5
PW Depth= 56mm
PW Gate= 4.0mm
PW Gain= 4dB

Sweep=50mm/s

.40
m/s
20

[redacted] I, 1980

ZA NEFROLOGIJO, KC LJUBJANA

10 May 17

09:36:29
0sec

L.LEDV.

----1----
V1 = 3.04m/s
V2 = 0.77m/s
RI = 0.75
S/D = 3.93
----2----
V = 3.12m/s
PG = 38.9mmHg
±Mean = 0.30m/s

4C1-S
4.0MHz 140mm
Abdomen
General /V

30dB 2 •/+1/2/5
PW Depth=116mm
PW Gate= 4.0mm
PW Gain= 9dB

Sweep=50mm/s

PW:3MHz HPRF

3.0
m/s
1.0

2D/CD/Dop Delete Set Lock Set Select Set